



## classic flexible spine

Fully flexible and designed for hands-on demonstrations. Features full male pelvis and occipital plate, L3-L4 disc prolapsed, spinal nerve exits and cervical vertebral artery (stand **D** sold separately below).

12-4529	flexible spine, 29", 4 lb	147.50
12-4530	flexible w/ femurs, 33", 5 lb	157.50
12-4531	flexible w/ femurs, painted, 33", 5 lb	220.00
<b>A</b> 12-4532	spine with female pelvis, 29", 4 lb	200.00

## didactic flexible spine

The same features as the Classic Flexible Spine with didactic painting to differentiate the five sections of the spinal column.

12-4536	didactic flexible spine, 29", 4 lb	225.00
<b>B</b> 12-4537	didactic spine w/ femurs, 32", 5 lb	255.00

## BONElike™ youth vertebral column

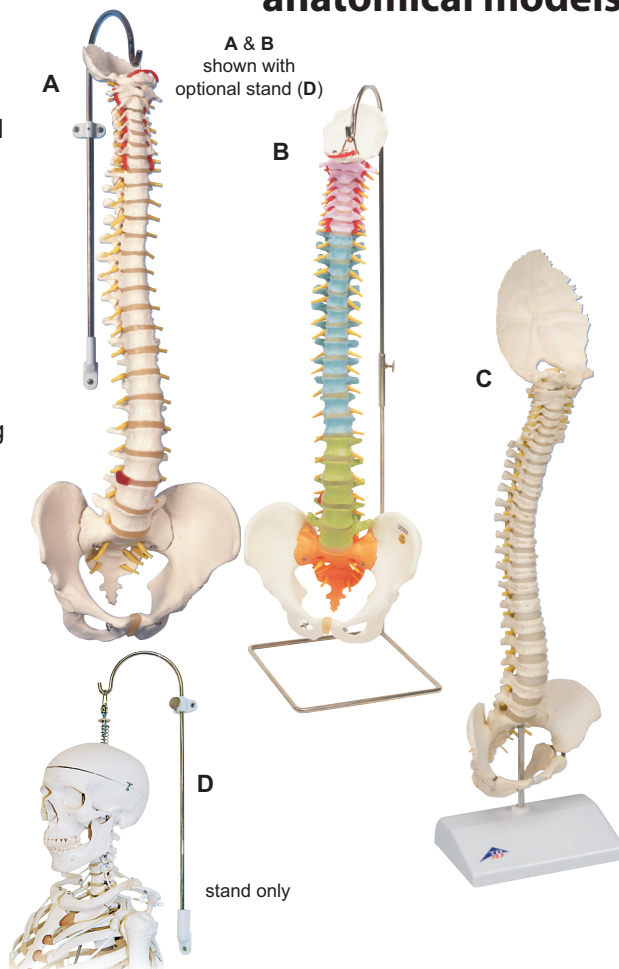
A model of a 5 year-old child's vertebral column. Flexible vertebral column includes occipital plate, pelvis and sacrococcyx. Within the spinal canal, the spinal cord with cauda equina and exiting nerve roots are represented in flexible material.

<b>C</b> 12-4545	youth vertebral column	312.50
------------------	------------------------	--------

## multifunctional stand for spines & skeletons, 3-part

Can be placed on the floor or mounted on the wall. Nickel-plated steel.

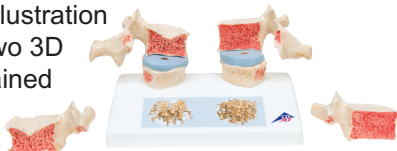
<b>D</b> 12-4546	multifunctional stand, 2 lb	72.50
------------------	-----------------------------	-------



## osteoporosis model

Magnetic model compares osteoporotic and normal thoracic vertebrae using T11 and T12. Reproductions of sequential osteoporotic thoracic vertebrae with narrower intervertebral discs are located on the left of the stand; two healthy vertebrae with discs are on the right side. A detailed illustration on the base depicts two 3D micro CT images obtained from bone biopsies.

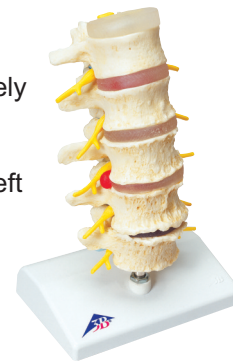6" x 4" x 4"; 1 lb



12-4544	osteoporosis model	102.50
---------	--------------------	--------

## vertebral degeneration model

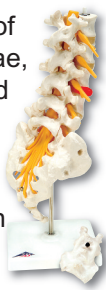Natural cast model illustrates degenerative changes to the vertebrae and intervertebral discs of the lumbar spine in five progressively serious degrees: from healthy disc and vertebrae all the way to very severe degeneration and bony constriction of the left intervertebral foramen with pressure on the spinal nerve root L5. 9"; 1 lb



12-4542	vertebral degeneration	197.50
---------	------------------------	--------

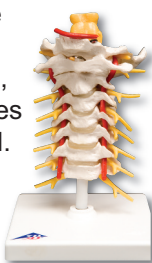## prolapsed lumbar section

Natural cast. Consists of the five lumbar vertebrae, sacrum, spinal cord and paired spinal nerves. A section of the sacrum shows the branching cauda equina. Also with L3-L4 dorso lateral prolapse. 13"; 1 lb



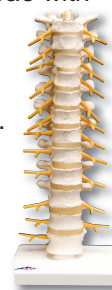## cervical section

Consists of occipital plate, the 7 vertebrae with discs, cervical nerves, vertebral arteries and spinal cord. 7"; 1 lb



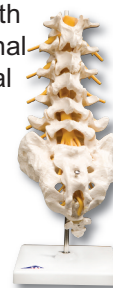
## thoracic section

12 thoracic vertebrae with discs, thoracic nerves and spinal cord. Flexibly mounted on stand. 13"; 1 lb



## lumbar section

5 lumbar vertebrae with discs, sacrum with flap, coccyx, spinal nerves and spinal cord. 13"; 1 lb



12-4543	prolapsed lumbar section	135.00	12-4539	cervical	100.00	12-4540	thoracic	100.00	12-4541	lumbar	107.50
---------	--------------------------	--------	---------	----------	--------	---------	----------	--------	---------	--------	--------